

Tuberculosis of Gallbladder: Report of A Rare Case

Biplab Kr Biswas¹, Subrata Pal², Arnab Mondal³, Kingshuk Bose¹, Mrinal Sikder⁴.

²(Department of Pathology, College of Medicine and Sagore Dutta Hospital, India)

¹(Department of Pathology, Bankura Sammilani Medical College, India)

³(Department of Surgery, Bankura Sammilani Medical College, India)

⁴(Dept of Pathology, Culcutta National Medical College, Kolkata, India)

Abstract: Tuberculosis of gallbladder is an extremely rare entity even in endemic region. Pre-operative diagnosis may not be possible and most of the cases are found incidentally during histopathological examination of resected specimen of gallbladder. We are presenting a case of tuberculosis of gallbladder presenting as acalculous cholecystitis in a middle aged female patient. We conclude that each gallbladder specimen should be sent for histopathological evaluation to rule out tuberculosis.

Keywords : Tuberculosis, gallbladder, cholecystitis.

I. Introduction

Gastrointestinal tuberculosis is common in developing countries. But tuberculosis of gall bladder is very rare even in endemic region^{1,2}. Till now very few cases have been reported in the English literature³. Most of the cases are diagnosed unexpectedly during histopathological evaluation because clinical features and laboratory tests are non-specific. Here we are presenting a case of tuberculosis of gallbladder presenting as chronic cholecystitis in a middle aged female patient.

II. Case Report

A 42 year female patient presented with intermittent pain at right hypocondrium and intolerance to fatty meal for one month. She had no history of fever, weight loss and jaundice. On examination, she had mild tenderness at right upper quadrant but no hepatosplenomegaly and lymphadenopathy were noted. On laboratory evaluation routine blood examination, liver function tests and other blood biochemistry reveal elevated erythrocyte sedimentation rate, leukocytosis (11,550/mm³) and mild anemia (haemoglobin-9gm%). Chest x-ray was normal and Mantoux test was negative. On ultrasound evaluation, gall bladder appeared minimally thickened and contained sludge. Common bile duct (CBD) appeared normal. Other abdominal organs appeared normal and no ascites was noted. Patient was operated by open cholecystectomy. During operative procedure gall bladder was adhered with the liver bed and omentum. Patient recovered successfully in postoperative period. On gross examination of cholecystectomy specimen, the gall bladder was 7x3 cm and wall thickness was 0.8cm. Surface was non-bile stained and contracted. Histopathological examination of gallbladder specimen revealed multiple caseating granulomas at mucosal and muscular layers admixed with many Langhans giant cells and lympho-plasmocytic infiltrate. Zeehl Neelson staining of section failed to reveal acid fast bacilli. Histopathological diagnosis was tubercular cholecystitis.

Patient was further treated with anti-tubercular drugs for six months (intensive phase with four drugs for 2 months and continuation phase with two drugs for 4 months). The patient was completely symptom free and did not reveal any pathology on abdominal ultrasound after one year follow up.

III. Discussion

Abdominal tuberculosis is common in developing countries and is increasing in the population having high incidence of human immunodeficiency virus infection^{1,4}. But tuberculosis of gallbladder is extremely rare pathology^{1,2}. After the first case reported by Gaucher (1870), only small number of cases reported so far⁵. Previous authors have suggested the causes of rarity of gallbladder tuberculosis as high alkalinity of bile and bile acids which inhibits the growth of tubercle bacillus^{1,2,6}. Most of the previous reported cases were associated with gall stone⁷. Cystic duct obstruction leading to low bile acid concentration in bile and damage of gallbladder mucosa due to gall stones are supposed to be the causes of gallbladder tuberculosis in cases reported with coexistent gall stones^{1,2,6,8}. In tuberculous acalculous cholecystitis cystic duct obstruction may be due to cholangitis, involvement by granulomatous disease or compression by lymph nodes around the duct⁹. Tuberculous infection spreads to gallbladder either by haematogenous or lymphatic spread from nearer foci or serosal spread from peritoneal lesion or canalicular dissemination^{7,9}.

Tuberculosis of gallbladder occurs mostly in women over 30 years and clinically presents with right hypochondriac pain, anorexia, nausea, vomiting with or without palpable mass^{1,7}. Clinical presentation strongly mimics chronic cholecystitis or carcinoma of gallbladder^{1,2,7}. Our case has presented with similar clinical features and diagnosed as chronic cholecystitis. Ultrasound and CT scan may reveal an enlarged gallbladder with wall thickening, soft tissue mass, or a nodular lesion but these are non-specific^{1,7,8}. Laboratory investigations may reveal elevated ESR, positive mantoux tests and occasionally elevated liver enzymes^{1,2}. In our case the patient had elevated ESR but mantoux test was negative and liver function test was normal. Histopathology is the gold standard for diagnosis of tuberculous cholecystitis and in our case also it accidentally diagnosed the proper etiology^{1,2,4,7,8}. Treatment of gall bladder tuberculosis needs anti-tubercular drug therapy with HRZE for two months (intrinsic phase) and HR for another four months (continuation phase).

On conclusion, tuberculous cholecystitis is rare but diagnosis is important because it needs anti-tubercular therapy. Pre-operative diagnosis is often not possible. So it is mandatory to send all cholecystectomy specimens for histopathological evaluation to rule out tuberculosis.

IV Figures

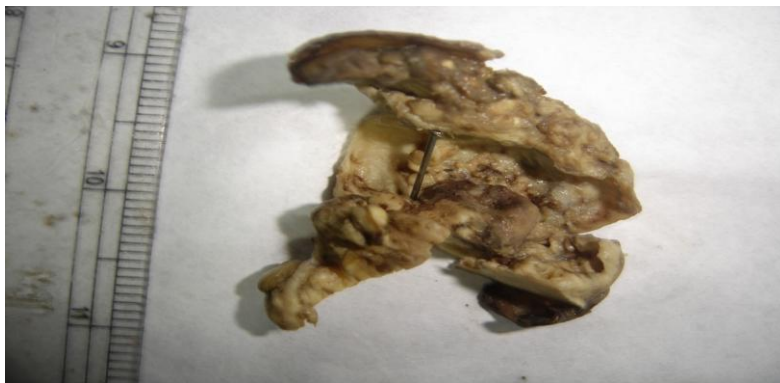

Figure 1: Image shows the gross picture of the gallbladder specimen in a case tuberculous cholecystitis.

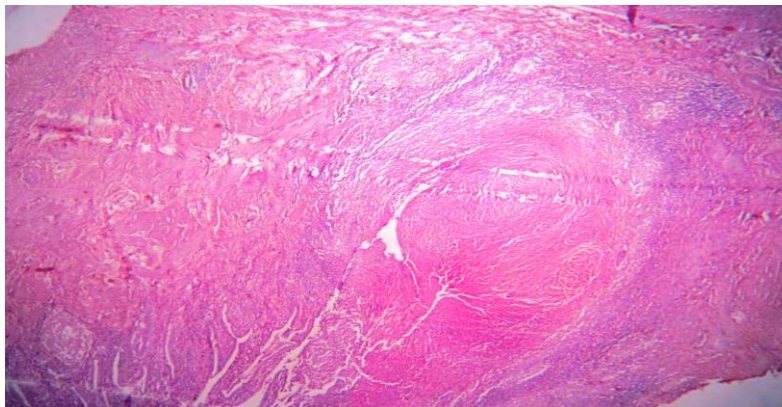


Figure 2: Photomicrograph shows central caseous necrosis, epithelioid granulomas and chronic inflammatory infiltrates in tuberculous cholecystitis (H & E stain, scanner view).

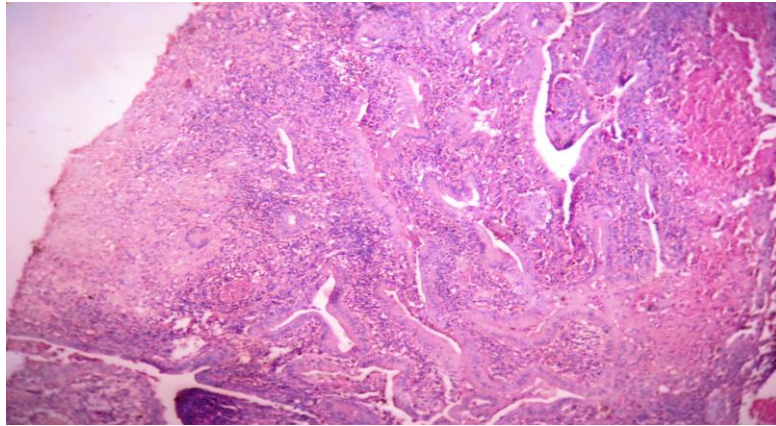


Figure 3: Photomicrograph shows epithelioid granulomas, Langhans giant cells caseous necrosis and chronic inflammatory infiltrates in tuberculous cholecystitis (H & E stain, 10X view).

References

- [1]. Akhtar K, Zaheer S, Ahmad SS, Mansoor T. Gall bladder tuberculosis. *Ann Trop Med Public Health* 2009;2:61-62.
- [2]. Tanwani R, Sharma D, Chandrakar SK. Tuberculosis of gall bladder without associated gallstones or cystic duct obstruction. *Indian J Surg* 2005;67:45-46.
- [3]. Ali Abdelbasit E, Shibly El Tahir M El, Sheikh Hassan El. Tuberculous gallbladder mass in a 7-year-old child with chronic right upper quadrant pain. *Sudan Med J* 2011;47(1):32-35.
- [4]. Xu X-Fang, Yu Ri-Sheng, Qiu Ling-Ling, Shen J, Dong Fei and Chen Ying. Gallbladder tuberculosis: CT findings with histopathologic correlation. *Korean J Radiol* 2011;12(2):196-202.
- [5]. Swain B, Otta S, Mohapatra S. Tuberculous cholecystitis. *Indian J Med Microbiol* 2013;31:317.
- [6]. Tauro LF, Martis JJ, Shenoy HD. Tuberculosis of gall bladder presenting as empyema. *Saudi J Gastroenterol* 2008;14:101.
- [7]. Ramia JM, Muffak K, Fernández A, Villar J, Garrote D, Ferron JA. Gallbladder tuberculosis: False-positive pet diagnosis of gallbladder cancer. *World J Gastroenterol* 2006; 12(40):6559-6560.
- [8]. Yu R, Liu Y. Gallbladder tuberculosis: case report. *Chin Med J (Engl)* 2002; 115: 1259-1261.
- [9]. Vilaichone R and Mahachai V. Tuberculous Acalculous Cholecystitis: A Case Report. *J Infect Dis Antimicrob Agents* 2005;22:127-131.